

Cerebrovascular acetazolamide reactivity and platelet function in asymptomatic cerebral thrombosis

M. Oishi*, Y. Mochizuki

Department of Neurology, Nihon University Nerima Hikarigaoka Hospital, 2-11-1 Hikarigaoka, Nerima-ku, Tokyo 179-0072, Japan

Received 10 August 1998; received in revised form 19 February 1999; accepted 4 May 1999

Abstract

In order to find out the relationship between the cerebrovascular acetazolamide reactivity and platelet function in asymptomatic cerebral thrombosis, 10 cases of asymptomatic cerebral infarction and 10 age-matched control subjects were studied. The cerebrovascular acetazolamide reactivity was measured using xenon computed tomography method. As markers of platelet function, the plasma concentrations of platelet factor 4, β -thromboglobulin, thromboxane B₂, and 11-dehydrothromboxane B₂ were determined. The cerebrovascular acetazolamide reactivity was significantly lower in the asymptomatic cerebral infarction group than in the control group. The plasma concentrations of platelet factor 4, β -thromboglobulin, thromboxane B₂, and 11-dehydrothromboxane B₂ were higher in the asymptomatic cerebral infarction group than in the control group. There was a significant negative correlation between the cerebrovascular acetazolamide reactivity and the plasma concentrations of platelet factor 4, β -thromboglobulin, thromboxane B₂, and 11-dehydrothromboxane B₂. The low cerebrovascular acetazolamide reactivity is considered to be related to platelet activation in asymptomatic cerebral thrombosis. © 1999 Elsevier Science B.V. All rights reserved.

Keywords: Cerebral blood flow, Platelet factor 4, β -Thromboglobulin; Thromboxane B₂; 11-Dehydrothromboxane B₂

1. Introduction

Acetazolamide is considered to dilate the cerebral arterioles by inhibiting the carbonic anhydrase in the red blood cells and increasing CO₂ in the arterioles [1,2]. Acetazolamide has been used for examining cerebrovascular dilatory reserve capacity [3]. Cerebrovascular reactivity to acetazolamide or CO₂ has been reported to be decreased in cerebral infarction [4,5].

On the other hand, platelet activation has been reported to occur in cerebral thrombosis [6–10]. There were no reports on the relationship between cerebrovascular acetazolamide reactivity and platelet functions in cerebral thrombosis. Therefore, we measured the cerebrovascular

acetazolamide reactivity and platelet functions in patients with asymptomatic cerebral thrombosis.

2. Materials and methods

Ten consecutive patients with asymptomatic cerebral thrombosis and 10 age-matched controls (volunteers) without cerebrovascular diseases were studied with their informed consent. Asymptomatic cerebral thrombosis was defined as cerebral thrombosis with magnetic resonance imaging (MRI) evidence of cerebral infarction and without past history of stroke and without corresponding signs nor symptoms. All the patients had a high-intensity lesion on T₂-weighted images and proton density images with a diameter of more than 3 mm (typical case shown in Fig. 1). The mean diameter of a high-intensity lesion was 9 mm and all lesion were located in the distribution of penet-

*Corresponding author. Tel.: +81-3-3979-3611; fax: +81-3-3979-3787.

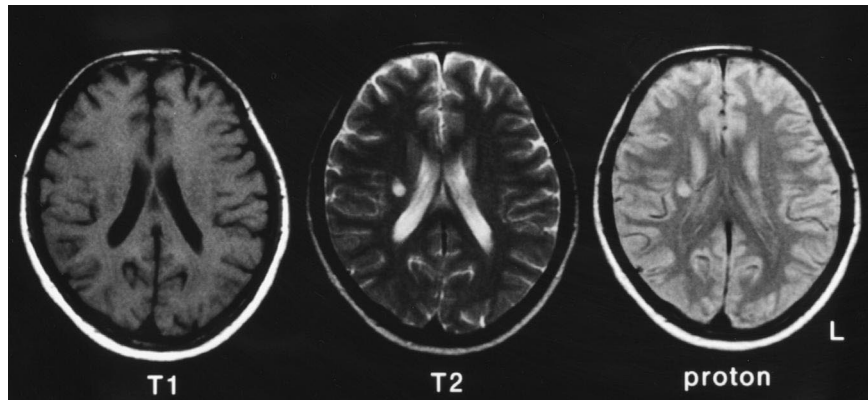


Fig. 1. Magnetic resonance imaging of the head in a patient with asymptomatic cerebral thrombosis.

rators. We did not include leuko-araiosis in MRI evidence of cerebral infarction. We did not include the patients taking anti-platelet medications or cerebral vasodilators. All the patients were examined with echocardiography (transthoracic and transesophageal) and ultrasound examination of the carotid artery and the patients with suspicion of cerebral embolism were excluded. The clinical profiles of the two groups were shown in Table 1. There was no statistically significant difference concerning hypertension, diabetes mellitus, hyperlipidemia, smoking, obesity, hematocrit and platelet count between the two groups.

The regional cerebral blood flow was measured using the stable xenon CT method [11–14]. The basal ganglia section and the lateral ventricle section parallel to the orbito-meatal line were studied. The subjects inhaled room air followed by a mixture of 30% xenon and 50% oxygen for 3 min. Serial scanning was performed once before xenon inhalation, three times in the wash-in process and five times in the washout process of 5 min. The serial scanning program consisted of a total of 18 scans consisting of nine serial scans on each section. The xenon concentration in the end-tidal expired gas was continuously recorded by the thermoconductivity method. We used the xenon delivery and analysis system (AZ-7000 model, Anzai Sogyo, Tokyo, Japan) and the CT equipment

(PreSage, Yokogawa Medical Systems, Tokyo, Japan). Round region of interest (ROI) with a diameter of 7 mm was used and the ROI was placed in the center of cerebral thrombosis. In bilateral frontal lobes, parietal lobes, temporal lobes and occipital lobes, the ROI was placed in the area where cerebral thrombosis was not adjacent. The cerebral cortex blood flow and cerebral white matter blood flow were calculated as the average of the blood flows in the eight areas.

The regional cerebral blood flow was measured before and 20 min after intravenous injection of 17 mg/kg acetazolamide. The cerebrovascular acetazolamide reactivity was defined as the increase rate of cerebral blood flow by acetazolamide.

The plasma platelet factor 4, β -thromboglobulin, thromboxane B_2 and 11-dehydrothromboxane B_2 were determined at the Special Reference Laboratories (SRL, Tokyo). At the SRL, platelet factor 4 and β -thromboglobulin were determined by enzyme immunoassay using International Standards [15], thromboxane B_2 and 11-dehydrothromboxane B_2 were determined by radioimmunoassay.

The blood drawing was performed using a polystyrene syringe and a 20-gauge needle according to the precautions [16]. The blood drawn was left for 15–30 min in the iced water and then was centrifuged at $2000\times g$ for 30 min at a temperature of 2–4°C.

Statistical analysis was performed using Mann–Whitney *U*-tests for comparison between the two groups and using Spearman's correlation coefficients for correlation between the cerebrovascular acetazolamide reactivity and the plasma concentration of β -thromboglobulin.

3. Results

Fig. 2 shows part of the actual record of the xenon CT of a single patient and a single control. The cerebrovascular acetazolamide reactivity is lower in asymptomatic cerebral thrombosis than in control.

Table 1
Clinical profiles of the two groups

	Asymptomatic cerebral thrombosis group	Control group
Number of cases	10	10
Age ^a	57.2±6.8	58.1±7.3
Male:female	6:4	6:4
Hypertension	6/10	5/10
Diabetes mellitus	3/10	2/10
Hyperlipidemia	4/10	2/10
Smoking	3/10	2/10
Obesity	2/10	3/10
Hematocrit (%) ^a	41.1±2.8	41.5±2.4
Platelet count ($\times 10^4$) ^a	27.5±3.2	28.2±3.5

^a Mean±standard deviation.

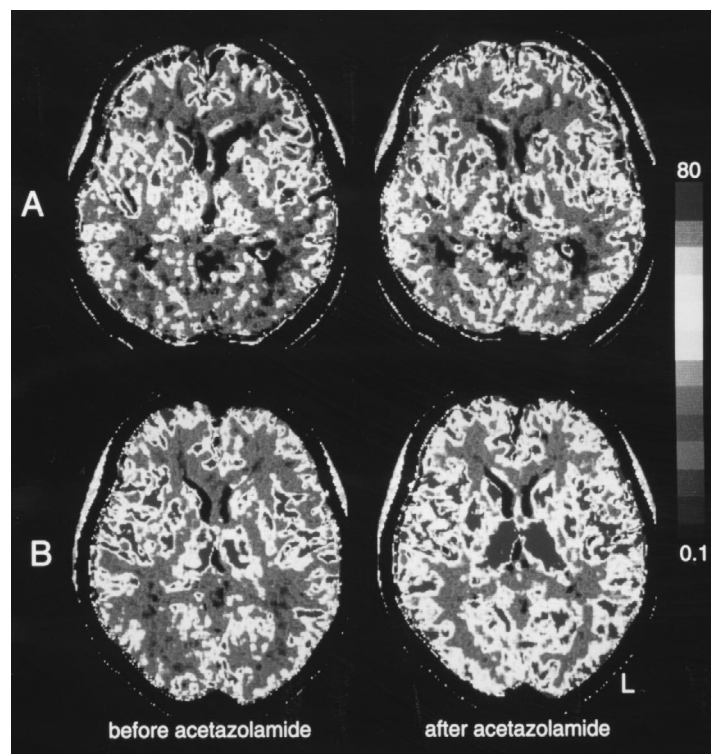


Fig. 2. Xenon computed tomography before and after intravenous injection of acetazolamide. (A) Asymptomatic cerebral thrombosis and (B) control.

Table 2 shows the comparison between the two groups. The cerebrovascular acetazolamide reactivity was significantly lower in the asymptomatic cerebral thrombosis group than in the control group. The plasma concentrations of platelet factor 4, β -thromboglobulin, thromboxane B_2 and 11-dehydrothromboxane B_2 were significantly higher in the asymptomatic cerebral thrombosis group than in the control group.

There were significant negative correlations between the cerebrovascular acetazolamide reactivity in the cerebral cortex and the plasma concentrations of platelet factor 4 ($r = -0.54$, $P < 0.05$), β -thromboglobulin ($r = -0.57$, $P < 0.05$), thromboxane B_2 ($r = -0.55$, $P < 0.05$) and 11-dehy-

drothromboxane B_2 ($r = -0.53$, $P < 0.05$). There were significant negative correlations between the cerebrovascular acetazolamide reactivity in the cerebral white matter and the plasma concentrations of platelet factor 4 ($r = -0.52$, $P < 0.05$), β -thromboglobulin ($r = -0.55$, $P < 0.05$), thromboxane B_2 ($r = -0.52$, $P < 0.05$) and 11-dehydrothromboxane B_2 ($r = -0.51$, $P < 0.05$).

4. Discussion

Platelet factor 4 and β -thromboglobulin were platelet-specific protein in the α granules of the platelets. When the

Table 2
Comparison between the two groups (mean \pm standard deviation)

	Asymptomatic cerebral thrombosis group	Control group
Cerebral cortex blood flow (ml/100 g per min)	61.7 \pm 9.3	68.2 \pm 9.6
Cerebral white matter blood flow (ml/100 g per min)	22.5 \pm 6.8	26.7 \pm 7.3
<i>Cerebrovascular acetazolamide reactivity (%)</i> :		
Cerebral cortex	41.3 \pm 6.5*	53.1 \pm 8.2
Cerebral white matter	35.7 \pm 5.8*	45.4 \pm 7.6
Plasma concentration of platelet factor 4 (ng/ml)	34.2 \pm 6.8**	12.1 \pm 5.3
Plasma concentration of β -thromboglobulin (ng/ml)	78.3 \pm 18.4**	39.1 \pm 15.7
Plasma concentration of thromboxane B_2 (pg/ml)	41.1 \pm 13.9*	28.2 \pm 11.4
Plasma concentration of 11-dehydrothromboxane B_2 (pg/ml)	15.7 \pm 2.6**	8.3 \pm 2.3

* $P < 0.05$; ** $P < 0.01$.

platelet is activated, the platelet factor 4 and β -thromboglobulin in approximately the same amount were released into the blood. Therefore, the ratio of platelet factor 4 and β -thromboglobulin is approximately 1:1 in the case of platelet activation in vitro. In the case of platelet activation in vivo, the ratio of platelet factor 4 and β -thromboglobulin is approximately 1:3 because the released platelet factor 4 combines with the endothelium of the blood vessel. In the present study, the ratio of platelet factor 4 and β -thromboglobulin was approximately 1:3 and suggests platelet activation in vivo.

Thromboxane A_2 is produced mainly in platelets and is metabolized to thromboxane B_2 with a half-life of approximately 30 s in the blood. Thromboxane B_2 is metabolized to 11-dehydrothromboxane B_2 and other metabolites in the liver and other organs. Thromboxane B_2 increases also in the case of platelet activation in vitro, but 11-dehydrothromboxane B_2 does not increase in the case of platelet activation in vitro. In the present study, thromboxane B_2 and 11-dehydrothromboxane B_2 concentrations were increased in the asymptomatic cerebral thrombosis group and this finding suggests platelet activation in vivo.

Platelet activation may be related to the pathogenesis of cerebral thrombosis [17]. Decreased cerebrovascular acetazolamide reactivity and slightly decreased cerebral blood flow in asymptomatic cerebral thrombosis suggests cerebral arteriolosclerosis. In the present study, patients with asymptomatic cerebral thrombosis were studied because they were not on anti-platelet medication such as aspirin. Decreased cerebrovascular acetazolamide reactivity and platelet activation may be related in cerebral thrombosis.

Although the associations between the measures may be simply an epiphenomenon, the negative correlation between the cerebrovascular acetazolamide reactivity and the plasma concentration of β -thromboglobulin in the present study suggests that the ischemic cerebrovascular disease is activating the platelets or platelet activation causes cerebrovascular disease.

References

- [1] Vorstrup S, Henriksen L, Paulson OB. Effect of acetazolamide on cerebral blood flow and cerebral metabolic rate for oxygen. *J Clin Invest* 1984;74:1634–9.
- [2] Frankel HM, Gracia E, Malik F, Weiss JK, Weis HR. Effect of

- acetazolamide on cerebral blood flow and capillary patency. *J Appl Physiol* 1992;73:1756–61.
- [3] Sullivan HG, Kingsbury TB, Morgan ME, Jeffcoat RD, Allison JD, Goode JJ, McDonnell DE. The rCBF response to Diamox in normal subjects and cerebrovascular disease patients. *J Neurosurg* 1987;67:525–34.
- [4] Maeda H, Matsumoto M, Handa N, Hougaku H, Ogawa S, Itoh T, Tsukamoto Y, Kamada T. Reactivity of cerebral blood flow to carbon dioxide in various types of ischemic cerebrovascular disease: evaluation by the transcranial Doppler method. *Stroke* 1993;24:670–5.
- [5] Mochizuki Y, Oishi M, Hara M, Yoshihashi H, Takasu T. Regional cerebral blood flow in lacunar infarction. *J Stroke Cerebrovasc Dis* 1997;6:137–40.
- [6] Uchiyama S, Takeuchi M, Osawa M, Kobayashi I, Maruyama S, Aosaki M, Hirosawa K. Platelet function tests in thrombotic cerebrovascular disorders. *Stroke* 1983;14:511–7.
- [7] Shah AB, Beamer N, Coull BM. Enhanced in vivo activation in subtypes of ischemic stroke. *Stroke* 1985;16:643–7.
- [8] Katayama Y, Terashi A, Shimizu J, Suzuki S, Kashiwagi F, Kamiya T, Ashida S. Role of platelets as a factor aggravating cerebral ischemia. *Jpn Circ J* 1990;54:1511–6.
- [9] Uyama O, Shimizu S, Nakanishi T, Nakahama H, Takiguchi A, Hayashi Y, Yamamoto S, Sugita M. Urinary 11-dehydrothromboxane B_2 : a quantitative index of platelet activation in cerebral infarction. *Intern Med* 1992;31:735–9.
- [10] Iwamoto T, Kubo H, Takasaki M. Platelet activation in the cerebral circulation in different subtypes of ischemic stroke and Binswanger's disease. *Stroke* 1995;26:52–6.
- [11] Johnson DW, Stringer WA, Marks MP, Yonas H, Good WF, Gur D. Stable xenon CT cerebral blood flow imaging: rationale for and role in clinical decision making. *Am J Neuroradiol* 1991;12:201–13.
- [12] Kashiwaki S, Yamashita T, Nakano S, Kalender W, Polacin A, Takasago T, Eguchi Y, Ito H. The wash-in/washout protocol in stable xenon CT cerebral blood flow studies. *Am J Neuroradiol* 1992;13:49–53.
- [13] Oishi M, Mochizuki Y, Hara M, Du C-M, Takasu T. Effects of intravenous L-dopa on P300 and regional cerebral blood flow in parkinsonism. *Intern J Neurosci* 1996;85:147–54.
- [14] Oishi M, Mochizuki Y, Hara M, Takasu T. Central motor conduction time in patients with periventricular lucencies. *J Neurol Sci* 1996;142:30–5.
- [15] Kerry PJ, Curtis AD. Standardization of β -thromboglobulin (β -TG) and platelet factor 4 (PF4): a collaborative study to establish international standards for β -TG and PF4. *Thromb Haemost* 1985;53:51–5.
- [16] Nell A, Kment G, Matejka M, Porteder H, Peskar BA, Sinzinger H. Abnahme, Präparation und Aufbewahrung menschlichen Plasmas zur radioimmunologischen Bestimmung von Thromboxan B_2 . *Wien Klin Wochenschr* 1988;100:700–6.
- [17] Uchiyama S, Takeuchi M, Osawa M, Kobayashi I, Maruyama S, Aosaki M, Hirosawa K. Platelet function tests in thrombotic cerebrovascular disorders. *Stroke* 1983;14:511–7.